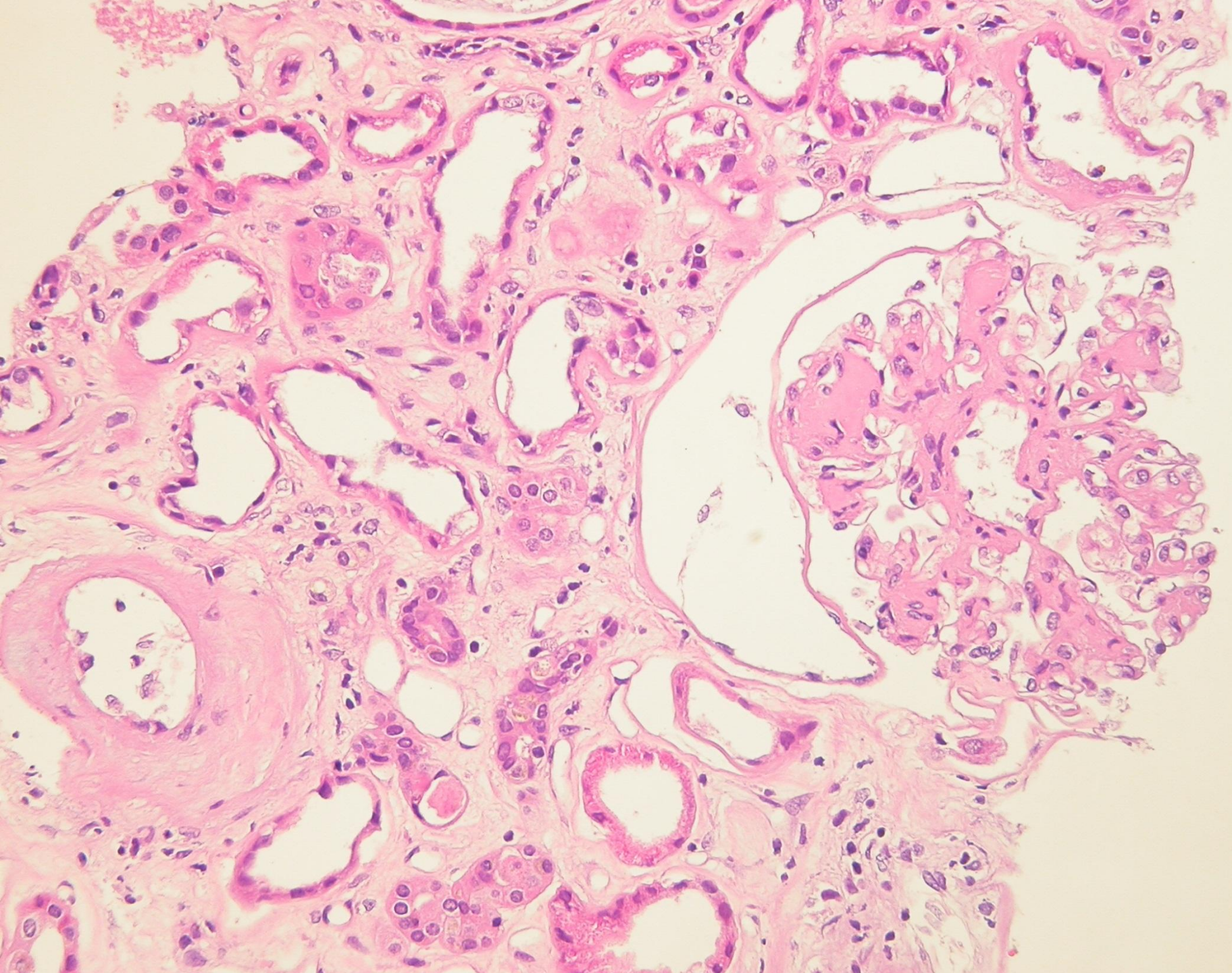
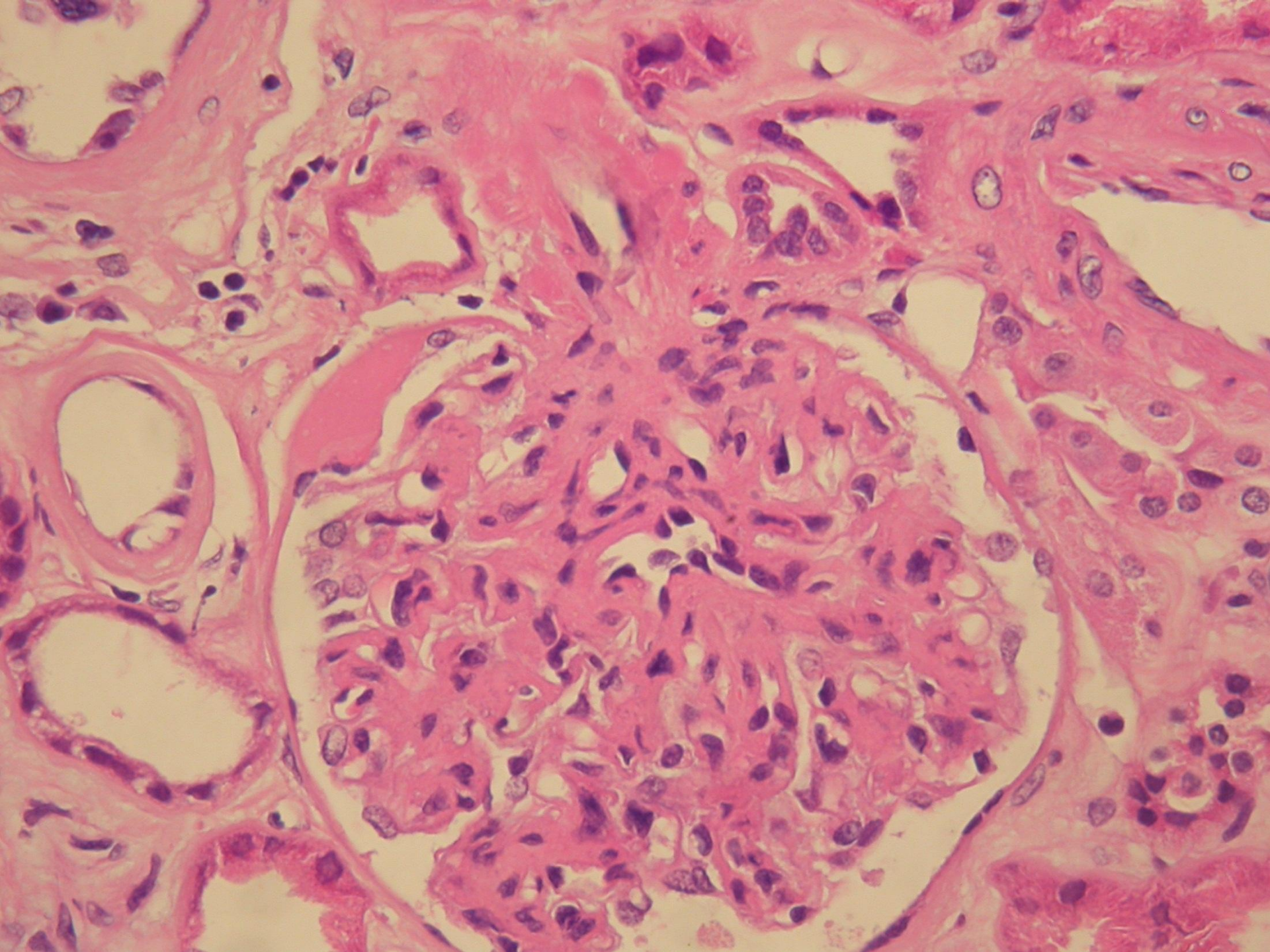
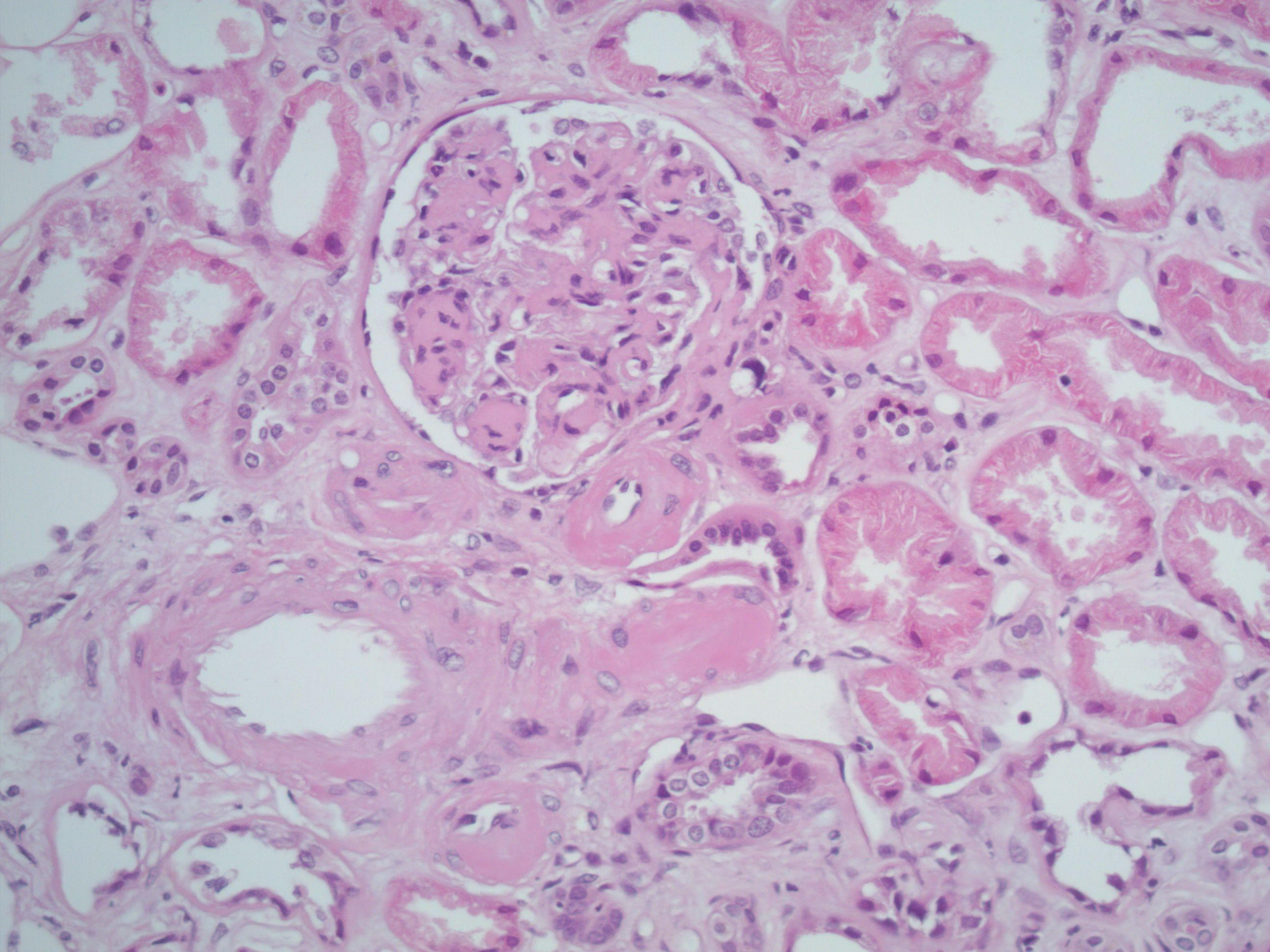


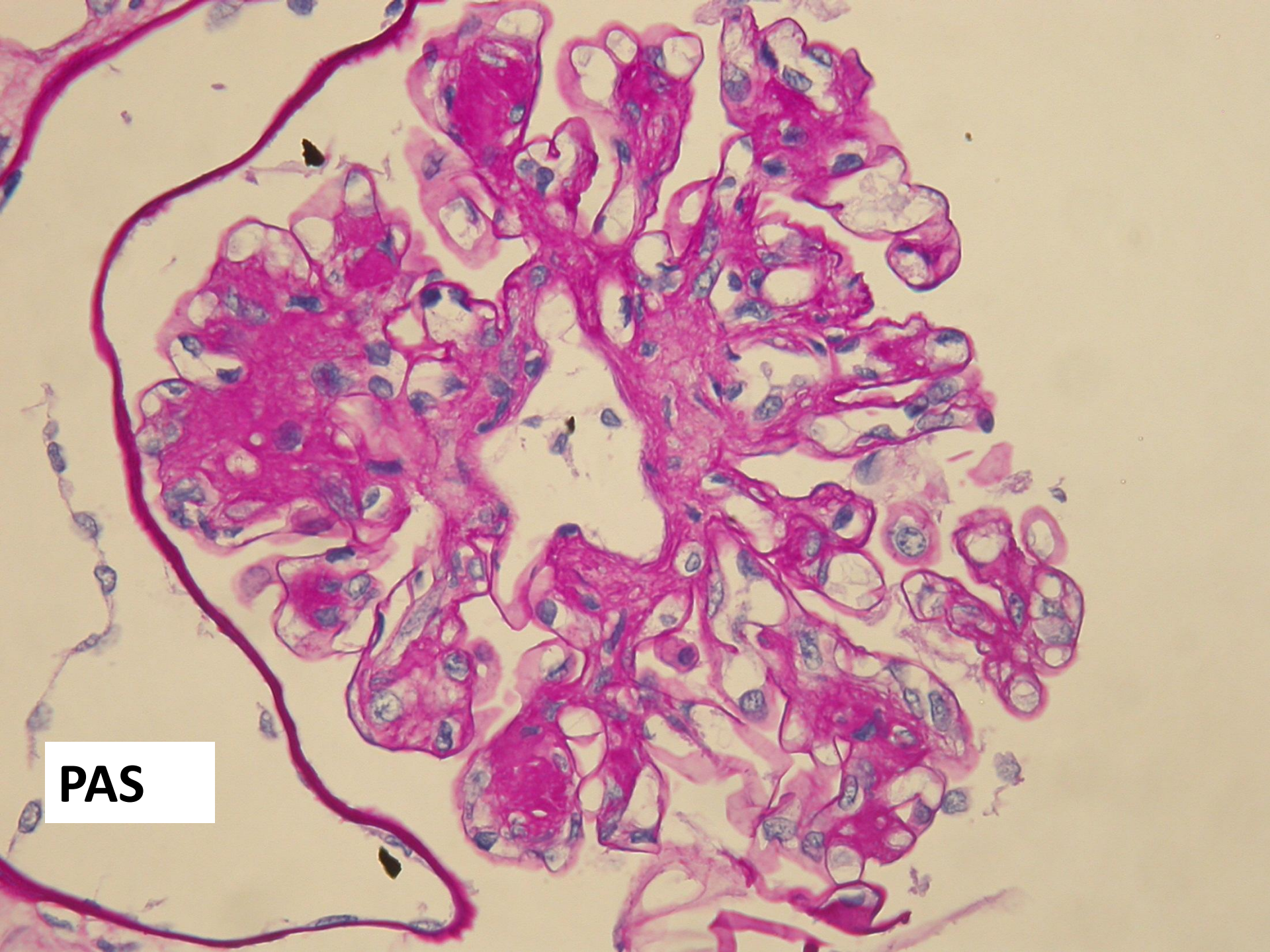
# Case 5

- Male aged 75.
- Haematoproteinuria
- Hypertension
- Ischaemic heart disease
- Diabetes type 2 – 3 year history
- Creatinine 200 - 4 year history of renal impairment i.e. CKD

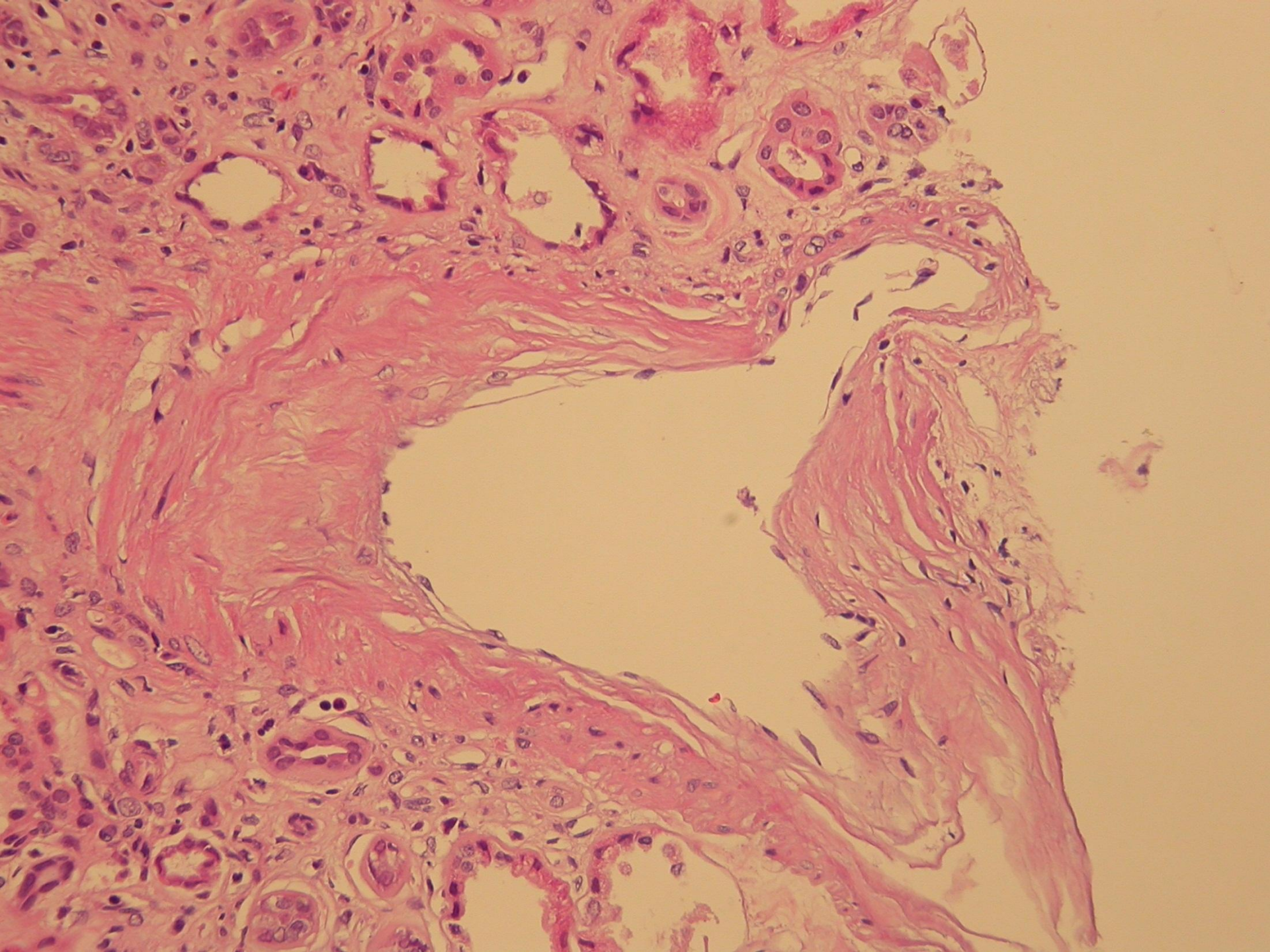


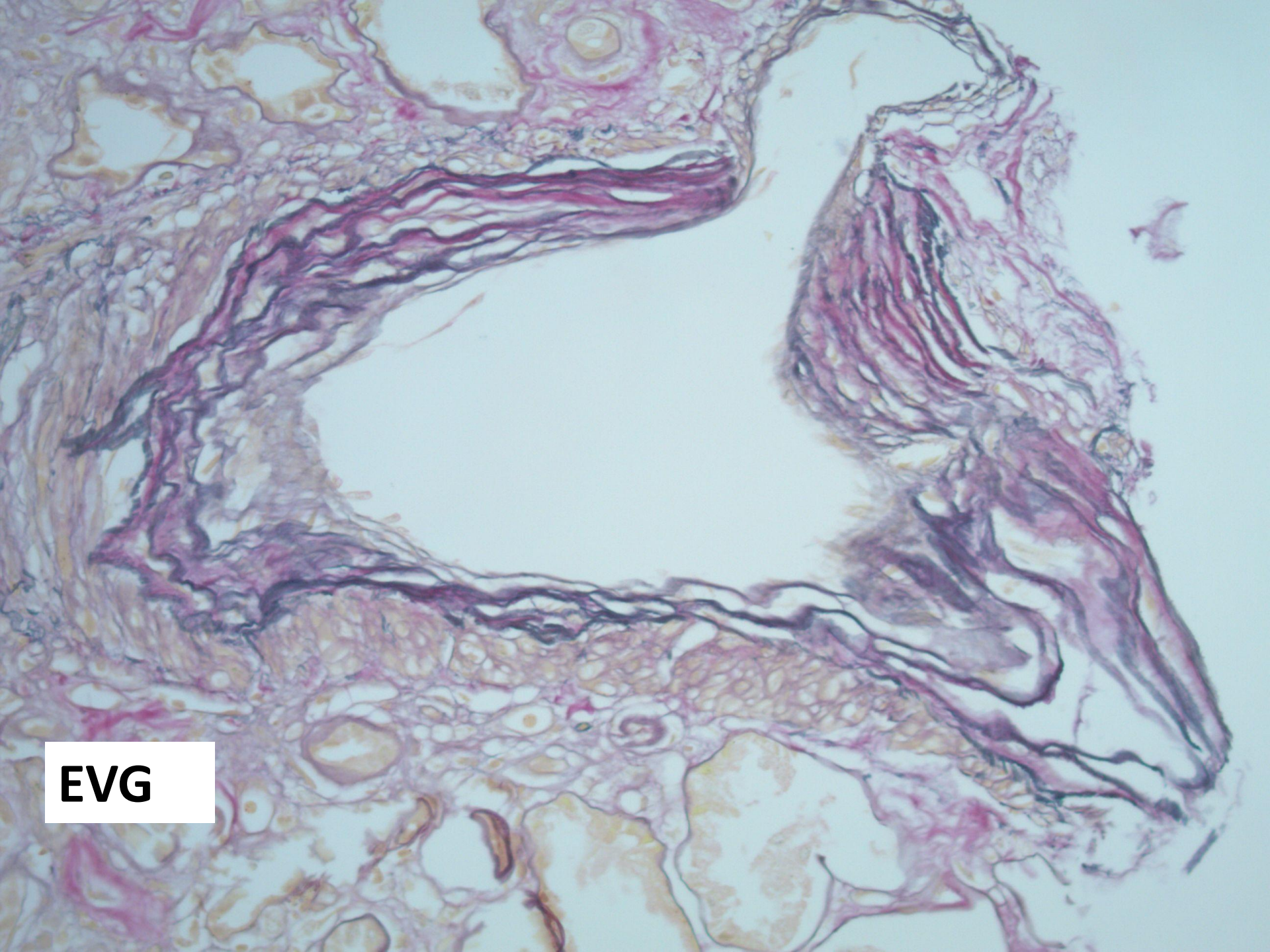




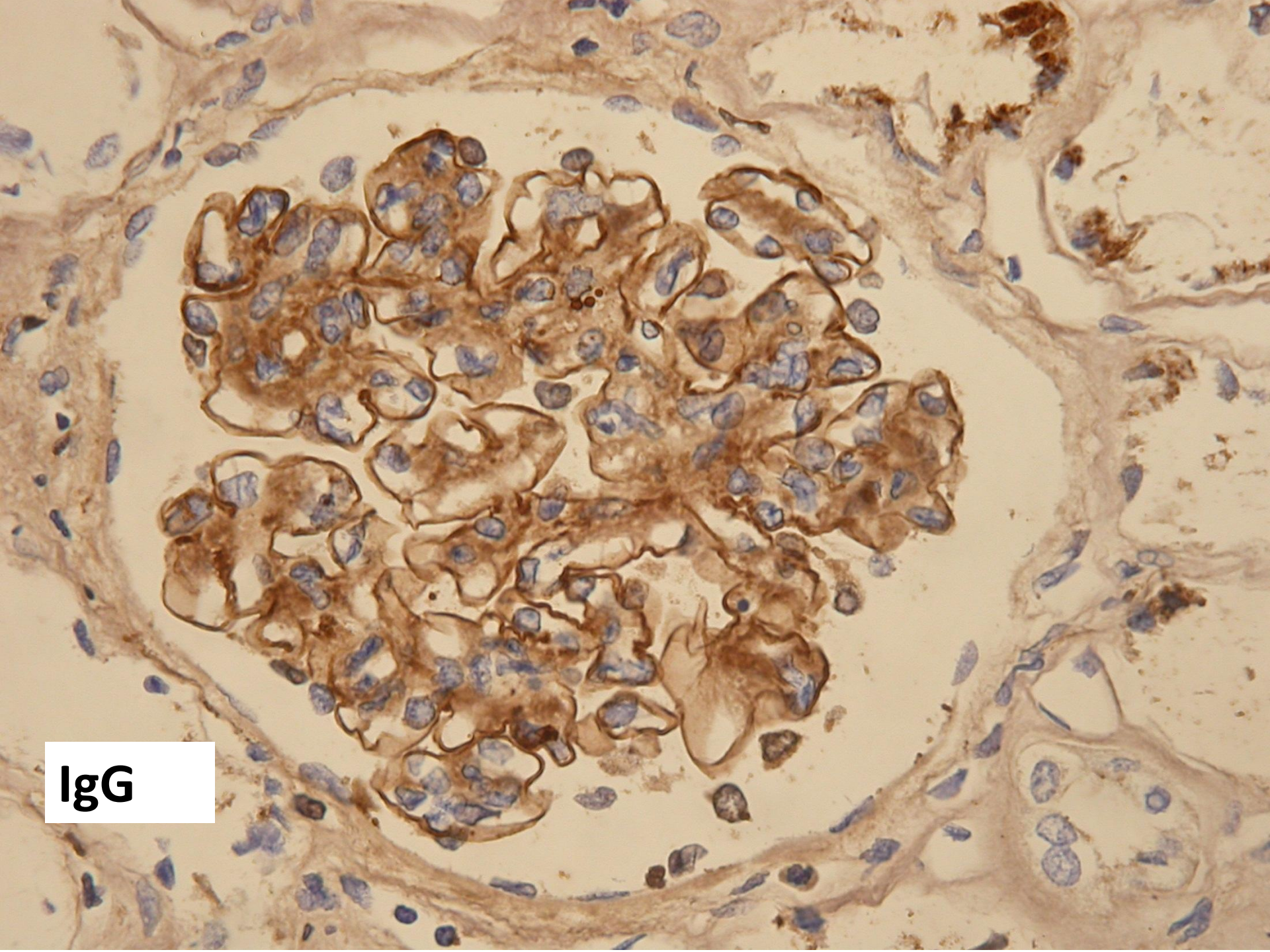


**PAS**





**EVG**

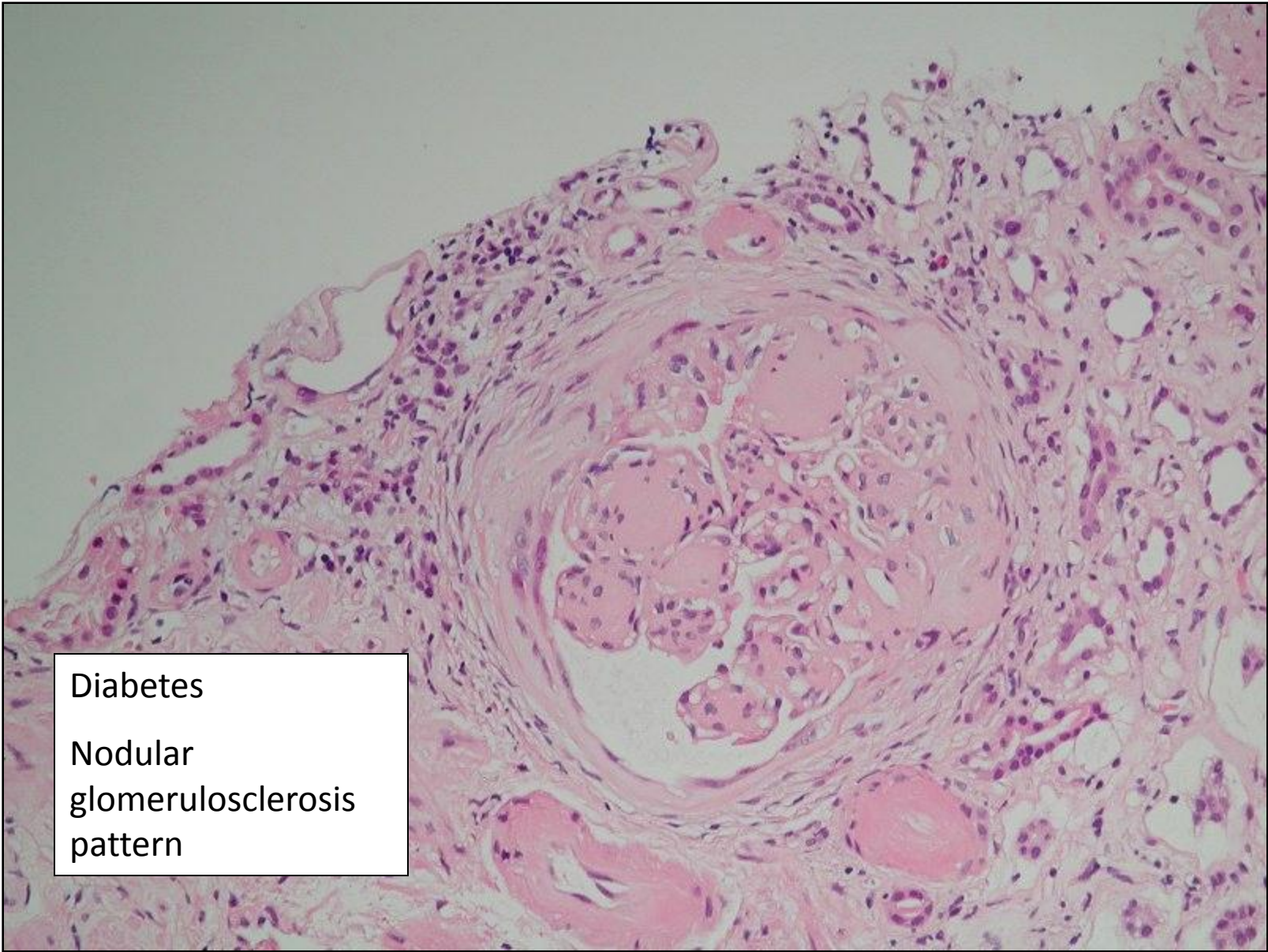


**IgG**

- What is the diagnosis?
- What other diagnoses are possible?
- What do you want to do to investigate further?

# Diabetes

- classically, diffuse and nodular glomerulosclerosis
- PAS positive material mesangium and capillary walls
- nodular glomerulosclerosis
- exudative (hyaline) lesions – fibrin cap, capsular drop
- EM – thickened basement membrane



Diabetes

Nodular  
glomerulosclerosis  
pattern